



EDMONDS ORTHOPEDIC CENTER

**COMPLETE CARE FOR YOUR PATIENTS**

- General Orthopedics
- Fracture care
- Sports Medicine
- Arthroscopy
- Minimally-invasive surgery
- Spine
- Shoulder & Elbow
- Hand & Wrist
- Hip & Knee
- Foot & Ankle
- Total Joint Reconstruction
- Physical Therapy
- Certified Hand Therapists
- Interventional Pain Management

**EDMONDS ORTHOPEDIC CENTER SURGEONS**

- James A. Alberts, MD
- Brian D. Cameron, MD
- Darcy S. Foral, MD
- L. Joseph Fowler, MD
- Wren V. McCallister, MD
- Jeffrey P. Remington, MD

# Focus on

# Claw Toes & Hammer Toes

DARCY S. FORAL, MD

MAY 2009

## Claw Toes & Hammer Toes

### WHAT IS IT?

Hammer toes, mallet toes and claw toes are in the category of toe disorders that range from minor and asymptomatic to painful and disabling. They are extremely prevalent in the population and the causes are multifactorial, ranging from poor fitting shoes to neurologic disorders. While the names are used somewhat interchangeably, the names are meant to describe which joints have a flexion or extension deformity. (Figure 1)

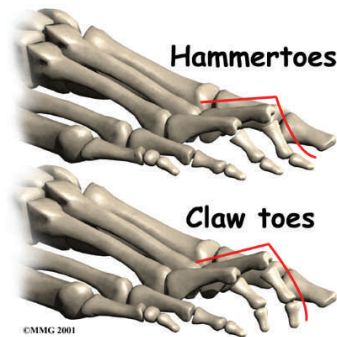


Figure 1

### HOW IS IT DIAGNOSED?

Patients usually begin to complain when the toes start to rub on shoes, making shoe wear difficult. They may get significant plantar foot pain from the metatarsal heads. As the toe starts to subluxate dorsally, it drives the metatarsal head into the bottom of the foot leading to plantar

keratosis and painful metatarsalgia with ambulation. Patients may also have pain over the top of the toe where it is rubbing the shoe, or at the end of the toe. It is important to make sure there is not a neurological etiology—especially with claw toes.

### HOW IS IT TREATED?

The goal of treatment is painless ambulation. Nonoperative measures include modification of shoe wear, orthotics, toe spacers and toe trainers. Metatarsal pads can be placed behind the metatarsal heads to off-load the painful area. Surgery ranges from minor with a quick recovery to more extensive, depending on the severity and whether or not the deformity is flexible or fixed. In general, toe deformities are easier to correct while still flexible. It is important to determine and correct the cause of the deformity or the recurrence rate will be high. Surgical treatment can include tendon transfers and lengthening, arthroplasty of the involved joint, realignment at the metatarsophalangeal joints and possible shortening of the metatarsal, if it is unusually long or the toe contracture is severe and long-standing.

Figure 2 (Claw toe) and Figure 3 (Hammer toe) depict the general

scheme for arthroplasty (reconstruction) of the involved joints.

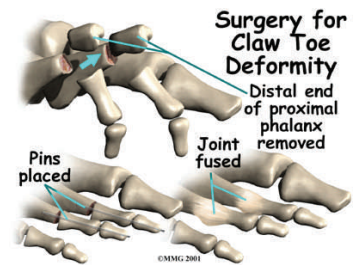


Figure 2

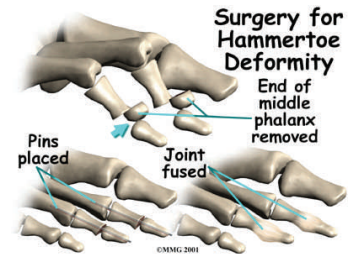


Figure 3

### WHAT TO DO NEXT?

While surgery may not be needed, it is important to determine early on the etiology of the toe deformity in order to provide the patient a sense of their prognosis and treatment options. All nonoperative options should be tried before surgery is considered, including changing shoe wear, stretching, padding, callus removal and investigation of any contributing factors.